




Available online at
ScienceDirect
www.sciencedirect.com

Elsevier Masson France
EM|consulte
www.em-consulte.com/en



Original Article

Reproducibility assessment of Delaire cephalometric analysis using reconstructions from computed tomography

A. Debelmas^{a,*}, S. Ketoff^a, S. Lanciaux^a, P. Corre^b, M. Friess^c, R.H. Khonsari^d

^aAssistance publique – Hôpitaux de Paris, Hôpital Pitié-Salpêtrière, service de chirurgie maxillo-faciale et stomatologie, Université Pierre et Marie Curie, Sorbonne Universités, 75013 Paris, France

^bService de stomatologie et chirurgie maxillofaciale, Centre Hospitalier Universitaire, Nantes, faculté de médecine, Université de Nantes, France

^cDépartement hommes, nature, sociétés, muséum national d'Histoire naturelle, CNRS UMR-7206, Paris, France

^dAssistance publique, Hôpitaux de Paris, Hôpital Necker, enfants malades, service de chirurgie maxillo-faciale et plastique, centre de référence des fentes et malformations faciales (MAFACE), Université Paris Descartes, Université Sorbonne Paris Cité, 75013, Paris, France

ARTICLE INFO

Article history:

Received 27 February 2019

Accepted 8 April 2019

Keywords:

Delaire cephalometric analysis
Intentional cranial deformations
Cephalometric X-rays
Tomography
Reproducibility

ABSTRACT

Introduction: Cephalometry performed on sagittal teloradiographic X-rays is commonly used for the planification of orthognathic procedures. Tomographic imaging techniques (computer tomography or cone-beam computer tomography) are more and more prescribed for the assessment of complex occlusofacial anomalies. In this study, we intended to evaluate if teloradiographic X-rays reconstructed from computer tomography (CT) can be used to trace reliable cephalometric analyses. We assessed the inter- and intra-observer reproducibility of a simplified Delaire analysis (Top 12), one of the numerous common cephalometric analyses, performed with the Delaire Evolution software on three sets of X-rays: (1) conventional cephalometric X-rays, (2) 2D reconstructions obtained from the CT scans of the same patients and (3) 2D reconstructions obtained from CT scans of dry skulls without a cervical spine (anthropological material). Our primary goal was to assess X-rays reconstructed from tomographies as an alternative for conventional cephalometric X-rays. Our secondary goal was to assess whether computerized cephalometric analysis was a reproducible technique, both on clinical and anthropological material.

Materials and methods: We included 10 consecutive adult patients admitted for orthodontic assessment who had benefited from both lateral cephalometric X-rays and from CT-scans. We also included 10 CT-scans from adult dry skulls without a cervical spine, from the collections of the Muséum National d'Histoire Naturelle (Musée de l'Homme, Paris, France). Cephalometric X-rays were reconstructed from CT-scans of both patients and dry skulls using Carestream[®] (Carestream Health inc., New York, USA). Simplified Delaire analyses (Top12) were conducted by 2 observers using the Delaire Evolution software (JDel, Nantes, France), on the 3 sets of cephalometric X-rays: (1) 10 standard cephalometric X-rays from the orthodontic patients, (2) 10 reconstructed cephalometric X-rays from the CT scans of the orthodontic patients and (3) 10 reconstructed cephalometric X-rays from the CT scans of the dry skulls. A standard statistical assessment of reproducibility was conducted using correlation coefficients.

Results: We found good inter- and intra-observer reproducibility for standard cephalometric X-rays and reconstructed cephalometric X-rays (Intraclass Correlation Coefficient > 0.75). We did not find any difference for angle measures between the standard cephalometric X-rays and the reconstructed cephalometric X-rays for the group of orthodontic patients ($P > 0.05$). Delaire cephalometric analysis was not reproducible for cephalometric X-rays without a cervical spine, that is for cephalometric X-rays reconstructed from the CT-scans of dry skulls.

Discussion: Delaire computerized simplified Top12 analysis was reproducible for lateral cephalometric X-rays and for reconstructions obtained from CT scans with similar angle measures for a given patient. This analysis does not seem to be reliable for dry skulls without upper cervical spine. This study uses the example of one particular computerized cephalometric analysis in order to show that cephalometric analyses can be performed on lateral reconstructed cephalometric X-rays obtained from CT scans.

© 2019 Elsevier Masson SAS. All rights reserved.

* Corresponding author at: Oral and maxillofacial surgery department, Pitié-Salpêtrière University Hospital, 47, boulevard de l'hôpital, 75013, Paris, France.
E-mail address: "A.Debelmas" alexandre.debelmas@hotmail.fr (A. Debelmas).

1. Introduction

Cephalometric analyses (CAs) are used in maxillofacial surgery and orthodontics in order to characterize growth anomalies and design treatment plans. Most of cephalometric analyses are performed in 2 dimensions on cephalometric lateral and frontal X-rays. Cephalometric X-rays rely on an X-ray source placed 1.5 meters away from the patient, and provides a 1:1 scaled image with minimum deformation: measures taken on these X-rays can therefore be directly used in clinical practice [1].

Here we focused on a specific sagittal cephalometric analysis, Delaire Architectural Analysis (DAA), performed on lateral cephalometric X-rays. Most of CAs rely on statistical data based on measures made on control 'normal' populations. These approaches are limited by the complexity of defining control groups [2]. Delaire analysis differs from the more usual statistical cephalometric approaches: DAA uses the cranial parameters of the patients as their own controls in order to define the ideal structure of their face [2,3]. Although DAA was initially designed based on speculative theories of craniofacial growth, several recent reports support its principles [4].

The present study had three main objectives:

- the assessment of the reproducibility of a computerized version of DAA;
- the assessment of the potential use of cephalometric X-rays reconstructed from CT scans as an alternative to standard cephalometric X-rays and;
- the assessment of the possibility of using DAA on cephalometric X-rays from dry skulls without a cervical spine.

We considered testing the reproducibility of DAA on dry skulls without a cervical spine as this analysis is often used by anthropologists, who have major issues in defining control groups and favor methods where the subject can be his/her own control. Most of the dry skulls we considered were carrying intentional deformations and had been included into previous works from our group [5,6].

Computed Tomography (CT) scans are commonly used nowadays, whereas they were less easily available for patients in the 1980's, when Jean Delaire created his analysis. However, despite the fact that most complex orthognathic surgery patients have a CT-scan available, 3D cephalometric analyses are not frequently used and most maxillofacial surgeons are more familiar with sagittal 2D analyses such as DAA. Interestingly, lateral cephalometric X-rays can be produced using CT data (based on the DICOM file format). It is therefore important to question the reproducibility of Delaire analysis performed on CT-generated 2D cephalograms [1], in order to avoid unnecessary exposure to radiations.

DAA is generally performed on tracing paper and requires approximately 10 minutes for a trained physician. Computerized tracing was proposed by Delaire in order to save time and share the measures more easily with other physicians. Moreover, computerized tracings generate data directly available for statistical assessment [2]. Here we used *Delaire evolution* (JDel, Nantes, France), the latest version of the Delaire analysis tracing softwares.

The precise aim of this study was to evaluate the inter- and intra-observer reproducibility of a simplified DAA (called *Top 12*) performed with *Delaire evolution*. In brief, measures obtained on the cephalometric X-rays of 10 control patients, referred to our department for various occlusal anomalies, were collected. These data were compared with the results of the same CA carried out on lateral 2D reconstructions obtained from CT scans of the same patients. We also assessed the inter- and intra-observer reproducibility of the same *Top 12* analysis performed on a series of CT-generated 2D cephalograms from dry skulls without a cervical

spine. These skulls, most of them carrying intentional deformations, were selected from the collections of the *Muséum National d'Histoire Naturelle* (*Musée de l'Homme*, Paris, France) and had been scanned for a previous study [6].

2. Material and Method

2.1. Inclusion criteria

We included 10 consecutive adult patients admitted for orthodontic assessment who had both standard lateral cephalometric X-rays and craniofacial CT-scans. We also included 10 CT-scans of dry skulls performed for a previous study [6].

2.2. Reconstruction Method

The reconstruction method used to produce lateral cephalometric X-rays from CT scans data was the same for the control and anthropologic subjects. We used Carestream[®] (Carestream Health inc., New York, USA) in order to generate a 3D reconstruction for each CT scan. Transparency and volume rendering protocols were adapted in order to superimpose all the craniofacial structures of interest on lateral views of the skull. Freehand superimposition was done directly in the software, giving priority to the outlines of the sphenoid and the anterior skull base. These structures took precedence over mandibular outlines when a complete superimposition of all the features was not possible (Fig. 1, Fig. 2).

2.3. Cephalometric tracing description

The 12 landmarks of the *Top 12* DAA were placed using *Delaire evolution* software by 2 observers on the 3 series of lateral cephalograms:

- 10 standard cephalometric X-rays from orthodontic patients;
- 10 lateral CT-generated 2D reconstructions of the same patients, and;
- 10 lateral cephalograms obtained from the CT scans of dry skulls without cervical spine.

Each observer placed the landmarks twice for all the 30 cephalometric X-rays and reconstructions with a one-month time interval.

Observer No. 1 was an experimented maxillofacial surgeon, Observer No. 2 was a 4th year maxillofacial registrar.

The twelve landmarks were placed, with the following order: N (Nasion, most anterior part of the frontonasal suture), M (Metanasion, junction of the nasofrontal, maxillofrontal, and maxillonasal sutures), Cla (anterior clinoid process), Clp (posterior clinoid process), Mp (posterior metanasion, intersection of C1, the line connecting M to Cla, and the posterior edge of the frontal process of the maxilla), Ara (intersection of the anterior curve of the condyle and the inferior border of the basilar process), Od (Odontoid process), Pti (lower end of the pterygomaxillary fissure), Pts (at the middle of the curve of the upper part of the pterygomaxillary fissure), ENa (anterior Nasal spine), Atl (Anterior Arc of the Atlas), Go (Gonion).

These landmarks were used to compute the following lines: C1 (superior line of the cranial base), C2 (craniofacial base line), C4 (connecting Od to Clp), F1, F2, F3, F4, F5, F7 and F8 (defined as the corresponding lines in 2D Delaire's analysis). Three major angles were then computed: the anterior skull base angle (between C1 and C2), the posterior skull base angle (between C1 and C4), and the facial angle 'adapted on the cranium' (between C1 and F1). Two other important features of the *Top 12* analysis were the ratios of the maxillary area Cmax (M-Pts segment on C2) and the

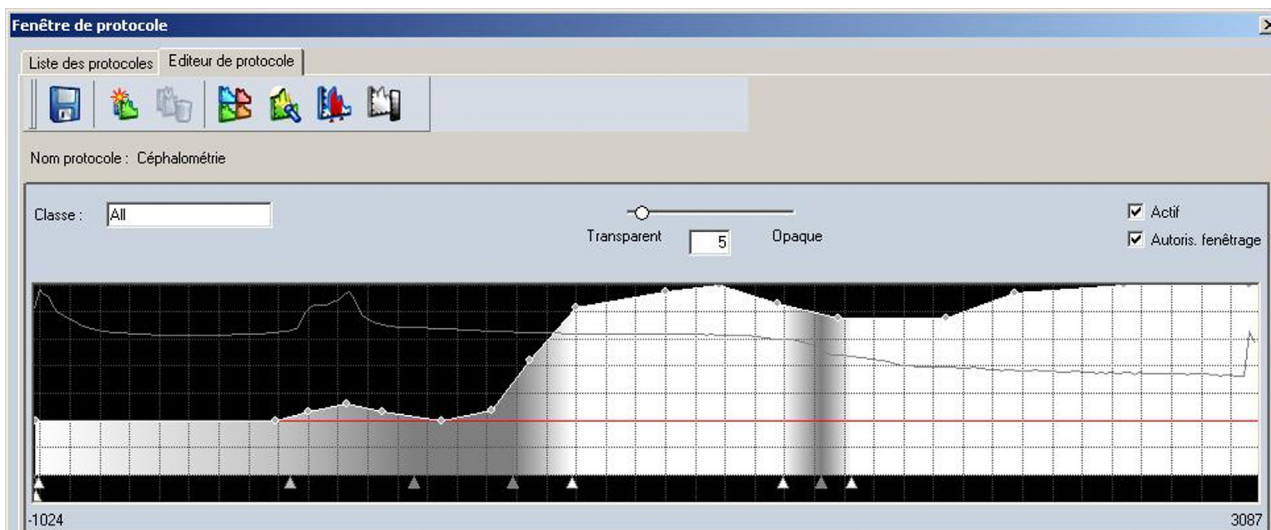


Fig. 1. Modified volume rendering protocol on Carestream[®], adapted for the generation of 2D lateral cephalograms using CT 3D data.

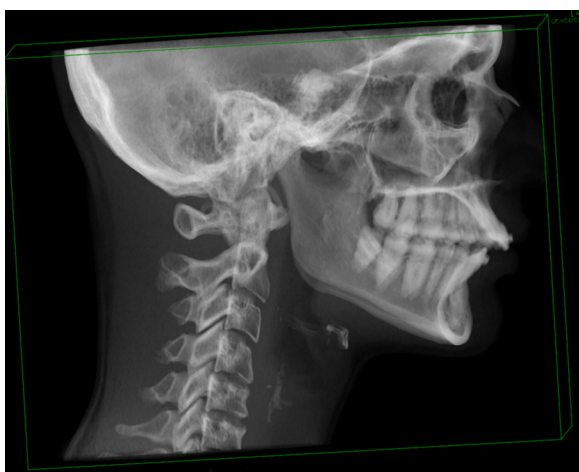

Fig. 2. Example of CT-generated lateral cephalogram. For superimposition of the left and right sides, skull base outlines were preferred to mandibular outlines.

mandibular area Cmand (segment of C2 connecting Pts to the most posterior part of the temporo-mandibular joint) over the craniofacial area CCF (segment of C2 connecting M to the most posterior part of the temporo-mandibular joint).

2.4. Specific features of the tracing on anthropological dry skulls

One particularity of anthropological dry skulls was the absence of upper cervical spine. It was therefore impossible to place Od and Atl using the usual method. We thus relied on two aspects of DAA:

- the line going through Od and Clp, C4, is supposed to reflect the basilar slope;
- in an ideal situation, F4 goes through Od.

As a consequence, we placed Od at the junction of the basilar slope and F4. Using the same method, we were able to place Clp on skulls with a damaged sella turcica, at the intersection of the basilar slope and C1.

Atl, usually located on the anterior arch of the atlas vertebra, at the tangent point of a line parallel to the Pti-Pts line was also impossible to place on anthropological skulls. Atl was arbitrarily

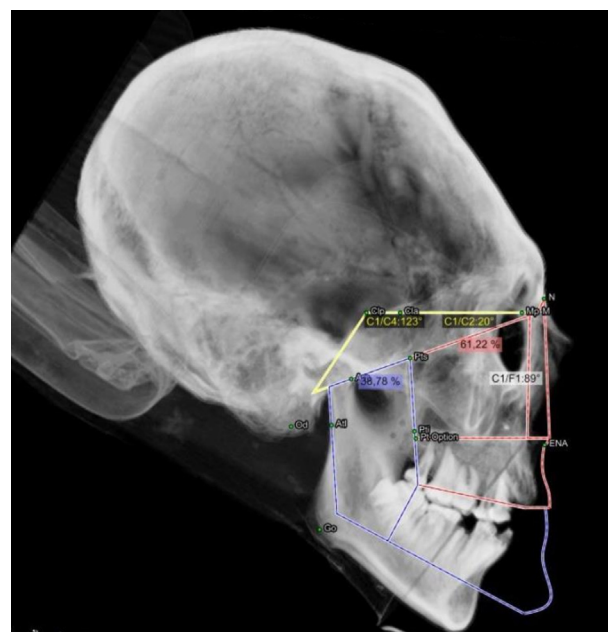


Fig. 3. Example of Top 12 cephalometric analysis performed on an anthropological dry skull without a cervical spine (intentionally deformed skull, circumferential type).

placed at the intersection of F4 and the posterior edge of the mandibular ramus (Fig. 3).

2.5. Statistical analysis

All the statistical analyses were conducted using SPSS statistics version 23 (IBM, Chicago, USA). The reliabilities of angle measurements (C1C2, C1C4, C1F1) and of the maxillary and mandibular areas over the craniofacial area (Cmax/CCF and Cmand/CCF) were assessed using the Intraclass Correlation Coefficient (ICC), in two ways mixed, absolute agreement, and average measures. ICCs obtained between the first and second tracings from the same observer reflected intra-observer reproducibility. ICCs obtained between the tracings from the two observers for each cephalogram reflected the inter-observer reproducibility. In accordance with the literature, we considered that ICCs > 0.75 reflected good reproducibility.

Table 1

Intra-observer reproducibility for observer No. 1 and for four parameters from the Top12 analysis (C1C2 angle, C1C4 angle, C1F1 angle, Cmand/CCF ration, Cmax/CCF ratio) was assessed using ICC (intraclass correlation coefficient), computed for the three groups: (1) orthodontic group, (2) reconstructed orthodontic group and (3) reconstructed dry skull group. ICC values are provided with their CI (95 % confidence interval). Red font: lower limit of the CI under 0.75; purple font: ICCs with CI including 0.

	C1C2	C1C4	C1F1	Cmand/Ccf	Cmax/Ccf
Control	0.948 (0.785;0.974)	0.967 (0.857;0.991)	0.975 (0.906;0.994)	0.958 (0.837;0.990)	0.958 (0.837;0.990)
Reconstructions	0.876 (0.520;0.969)	0.979 (0.922;0.995)	0.957 (0.803;0.990)	0.974 (0.893;0.993)	0.974 (0.893;0.993)
Anthropological	0.889 (0.535;0.973)	0.859 (0.464;0.964)	0.759 (0.053;0.940)	0.696 (−0.315;0.926)	0.696 (−0.315;0.926)

Table 2

Intra-observer reproducibility for observer No.2 and for four parameters from the Top12 analysis (C1C2 angle, C1C4 angle, C1F1 angle, Cmand/CCF ration, Cmax/CCF ratio) was assessed using ICC (intraclass correlation coefficient), computed for the three groups: (1) orthodontic group, (2) reconstructed orthodontic group and (3) reconstructed dry skull group. ICC values are provided with their CI (95 % confidence interval). Red font: lower limit of the CI under 0.75; purple font: ICCs with CI including 0.

	C1C2	C1C4	C1F1	Cmand/Ccf	Cmax/Ccf
Control	0.955 (0.815;0.989)	0.995 (0.976;0.998)	0.941 (0.768;0.985)	0.948 (0.802;0.987)	0.948 (0.802;0.987)
Reconstructions	0.943 (0.760;0.986)	0.987 (0.951;0.997)	0.926 (0.695;0.982)	0.959 (0.843;0.990)	0.959 (0.843;0.990)
Anthropological	0.606 (0.608;0.903)	0.324 (−0.637;0.799)	0.471 (−0.738;0.861)	0.920 (0.696;0.980)	0.920 (0.696;0.980)

Table 3

Inter-observer reproducibility. Op 1-1: First tracing of observer No. 1; Op 1-2: Second tracing of observer No. 1; Op 2-1: First tracing of observer No. 2; Op 2-2: Second tracing of observer No. 2.

	C1C2	C1C4	C1F1	Cmand_Cf	Cmax_Cf
Control					
op 1-1 vs op 2-1	0.937 (0.729;0.985)	0.984 (0.938;0.996)	0.938 (0.723;0.985)	0.911 (0.462;0.980)	0.911 (0.462;0.980)
op 1-1 vs op 2-2	0.857 (0.470;0.964)	0.981 (0.925;0.995)	0.914 (0.676;0.978)	0.855 (0.462;0.963)	0.855 (0.462;0.963)
op 1-2 vs op 2-1	0.903 (0.621;0.976)	0.927 (0.726;0.982)	0.854 (0.432;0.963)	0.868 (−0.012;0.973)	0.868 (−0.012;0.973)
op 1-2 vs op 2-2	0.816 (0.322;0.953)	0.937 (0.755;0.984)	0.821 (0.332;0.955)	0.868 (0.330;0.969)	0.868 (0.330;0.969)
Reconstructions					
op 1-1 vs op 2-1	0.875 (0.529;0.968)	0.952 (0.769;0.989)	0.942 (0.666;0.987)	0.949 (0.799;0.987)	0.949 (0.799;0.987)
op 1-1 vs op 2-2	0.949 (0.797;0.987)	0.958 (0.606;0.991)	0.924 (0.685;0.981)	0.942 (0.572;0.987)	0.942 (0.572;0.987)
op 1-2 vs op 2-1	0.903 (0.283;0.979)	0.947 (0.407;0.989)	0.911 (−0.012;0.983)	0.967 (0.835;0.992)	0.967 (0.835;0.992)
op 1-2 vs op 2-2	0.861 (0.478;0.965)	0.923 (0.375;0.984)	0.874 (0.323;0.971)	0.940 (0.509;0.987)	0.940 (0.509;0.987)
Anthropological					
op 1-1 vs op 2-1	0.609 (−0.258;0.896)	0.389 (−1.629;0.851)	0.763 (−0.023;0.942)	0.918 (0.392;0.982)	0.918 (0.392;0.982)
op 1-1 vs op 2-2	0.392 (−1.046;0.841)	−0.448 (−3.057;0.598)	−0.091 (−3.254;0.727)	0.937 (0.720;0.985)	0.937 (0.720;0.985)
op 1-2 vs op 2-1	0.668 (−0.112;0.913)	0.205 (−1.156;0.776)	0.512 (−0.825;0.876)	0.601 (−0.591;0.901)	0.601 (−0.591;0.901)
op 1-2 vs op 2-2	−0.568 (−0.399;0.886)	−0.065 (−0.768;0.591)	0.145 (−0.845;0.730)	0.858 (0.432;0.965)	0.858 (0.432;0.965)

ibility [1]. We then computed the ICCs for the same parameters between the standard cephalometric X-rays and the 2D CT-generated lateral cephalograms of the same control patients, to determine whether our reconstruction method would alter the reliability of the measurements. Moreover, we conducted a MANOVA analysis (Multivariate Analysis Of Variance) with a statistical level of significance of 5 % and with a null hypothesis stating that the radiological method (i.e. standard X-rays or CT-generated cephalograms) did not alter the angles measurements. The accuracy of landmark placement for all 3 series was assessed by computing the Euclidean distances between the first and second tracing for each observer, and between the two observers for each series of tracing, for each landmark. The threshold of acceptability for these distances was arbitrarily set to 2 mm. A Wilcoxon test was performed, displaying the median of these distances, and comparing them to the theoretical 2 mm threshold (statistical level of significance set to 5%). Euclidean distances were computed using the coordinates of the landmarks (x_1 , y_1) and (x_2 , y_2) in a 2D orthonormal system using the standard formula.

3. Results

We found good intra- and inter-observer reproducibility for all the measures on lateral cephalometric X-rays and CT 2D

reconstructions of control patients, with ICCs superior to 0.75. However, ICCs were mostly inferior to 0.75, with their 95% confidence intervals including 0, for anthropological cephalometric X-rays (Tables 1,2 and 3). A good correlation was found for all the parameters between the standard lateral cephalometric X-rays and the 2D reconstructions from the same patients, with ICCs superior to 0.75, for both observers, for every tracing (Table 4). Moreover, we did not find any significant difference in terms of angle measurements between these two imaging techniques ($P > 0.05$), which is consistent with our previous results (Table 1). The placement of Od, Pti, Pts and Atl landmarks was not accurate for the inter- and intra-observer comparisons in dry skulls without cervical spines: median distances between observer No. 1 and observer No. 2 for these landmarks were significantly superior to 2 mm (Tables 2,3,4).

4. Discussion

This study confirms results previously published in the literature: generating a lateral cephalogram using 3D data (CT-scan, Cone-Beam) does not alter the intra- and inter-observer reproducibility of cephalometric analyses in terms of angle measures [1]. Moreover, superimpositions and potential image scale modifications caused by divergent do not induce any

Table 4

Comparison between standard lateral cephalometric X-rays and CT-generated reconstruction from orthodontic patients. T1; T2: First and Second tracings for the standard lateral cephalometric X-rays. R1; R2: First and Second tracings for the 2D reconstructions from CT scans from the same patients.

	C1C2	C1C4	C1F1	Cmand/Ccf	Cmax/Ccf
Observer 1					
T1 vs. R1	0.935 (0.735;0.984)	0.951 (0.798;0.988)	0.942 (0.772;0.986)	0.933 (0.740;0.983)	0.933 (0.740;0.983)
T2 vs. R1	0.938 (0.752;0.985)	0.895 (0.596;0.974)	0.863 (0.468;0.966)	0.930 (0.700;0.983)	0.930 (0.700;0.983)
T1 vs. R2	0.904 (0.637;0.976)	0.932 (0.730;0.983)	0.931 (0.740;0.983)	0.945 (0.791;0.986)	0.945 (0.791;0.986)
T2 vs. R2	0.841 (0.395;0.960)	0.880 (0.501;0.971)	0.856 (0.406;0.965)	0.917 (0.660;0.980)	0.917 (0.660;0.980)
Observer 2					
T1 vs. R1	0.973 (0.893;0.993)	0.968 (0.763;0.993)	0.897 (0.601;0.974)	0.962 (0.846;0.991)	0.962 (0.846;0.991)
T2 vs. R1	0.947 (0.787;0.987)	0.974 (0.780;0.994)	0.918 (0.688;0.979)	0.932 (0.735;0.983)	0.932 (0.735;0.983)
T1 vs. R2	0.951 (0.601;0.990)	0.963 (0.552;0.993)	0.916 (0.676;0.979)	0.905 (0.627;0.976)	0.905 (0.627;0.976)
T2 vs. R2	0.944 (0.556;0.988)	0.970 (0.493;0.994)	0.903 (0.635;0.975)	0.928 (0.700;0.982)	0.928 (0.700;0.982)

significant error [1]. This report is the first reproducibility assessment for Delaire analysis, using standard and reconstructed data. Here we have also showed that producing a lateral cephalogram can be performed easily and reliably by 'freehand' superimposition of anatomical structures, without altering the intra- and inter-observer reproducibility of the cephalometric analysis. According to our results, it may not be necessary to re-irradiate patients who already underwent a head and neck CBCT or a CT-scan [1,7] in order to obtain a good quality lateral cephalometric X-ray.

Concerning the anthropological data, we failed to demonstrate sufficient reproducibility, especially inter-observers. We attributed this lack of reliability to the placement of the Odontoid (Od), superior and inferior Pterygoid (Pts and Pti) and Atlas (Atl) landmarks, since the median distances calculated for each pair of tracings per observer (intra-observer assessment) and between the two observers for each tracing (inter-observer assessment) were significantly superior to 2 mm.

4.1. Odontoid process and anterior arc of the Atlas landmarks: Od and Atl

Unlike control patients, dry skulls had no cervical spine, and thus no Odontoid process nor Atlas. Therefore, placing Od and Atl was not possible with the usual method as described by Delaire. The Od landmark is critical, even in a simplified analysis such as *Top12*. Indeed, the interactions between the craniocervical junction and the spheno-occipital synchondrosis are considered to have an important role in the vertical position of facial structures. Variations in C1F1 angle according to the posterior skull base angle are an illustration of this concept [3]. Unfortunately, the placement method we chose to account for the lack of cervical spine was not reproducible. Furthermore, placing the *Top12* landmarks on dry skulls was often difficult, not only because of the absence of cervical spine, but also due to the variable state of preservation of some anthropological skulls (post-mortem skull base fractures, modifications of mineralization by taphonomic processes).

4.2. Superior and inferior pterygoid landmarks: Pts and Pti

Pts and Pti define a line representing the orientation of the pterygomaxillary fissure, which corresponds to the direction of the masticatory forces [3]. In an ideal situation, this line intersects the calvaria at the Bregma (Br). Alterations of the cranial vault and

various superimpositions in the pterygomaxillary region were mostly responsible for the difficulties encountered when placing Pts and Pti.

4.3. Anterior and posterior Clinoid landmarks: Cla and Clp

It may not be accurate to attribute the insufficient reliability of the analysis on dry skulls only on the account of their quality of preservation. The placement of Cla and Clp is a counter-example of this hypothesis. In fact, even though the sella turcica was partially destroyed on several anthropological skulls, the placement of these landmarks was correct: the median distances were significantly inferior to 2 mm.

In brief, our results showed that Delaire computerized simplified analysis, *Top 12*, was reproducible on standard lateral cephalometric X-rays and on 2D CT-generated lateral cephalograms. Moreover, the reconstruction technique does not modify the results in terms of angle measures. This study emphasizes the fact that a cephalometric analysis can be conducted on CT-generated cephalometric reconstructions. However, this analysis is not usable on anthropological dry skulls without Odontoid process.

Disclosure of interest

The authors declare that they have no competing interest.

References

- [1] Chung RR, Lagravere MO, Flores-Mir C, Heo G, Carey JP, Major PW. A comparative analysis of angular cephalometric values between CBCT generated lateral cephalograms versus digitized conventional lateral cephalograms. *Int Orthod* 2009;7:308–21.
- [2] Delaire J, Salagnac JM, Notari J. Diagnostic des dysmorphoses dento-maxillo-faciales : apport de l'analyse architecturale informatisée. *Actual Odontostomatol (Paris)* 1994;187:477–510.
- [3] Delaire J, Schendel SA, Tulasne JF. An architectural and structural craniofacial analysis: a new lateral cephalometric analysis. *Oral Surg Oral Med Pathol* 1981;52:226–38.
- [4] Parsons TE, Downey CM, Jirik FR, Hallgrímsson B, Janniczky HA. Mind the gap: Genetic manipulation of basicranial growth within synchondroses modulated calvarial and facial shape in mice through epigenetic interactions. *PLoS One* 2015;10:e0118355.
- [5] Tubbs RS, Salter EG, Oakes WJ. Artificial deformation of the human skull: a review. *Clin Anat* 2006;19:372–7.
- [6] Khonsari RH, Friess M, Nysjö J, Odri G, Malmberg F, Nyström I, et al. Shape and volume of craniofacial cavities in intentional skull deformations. *Am J Phys Anthropol* 2013;151:110–9.
- [7] Olszewski R, Reychler H, Cosnard G, Denis JM, Vynckier S, Zech F. Accuracy of three-dimensional (3D) craniofacial cephalometric landmarks on a low-dose 3D computed tomograph. *Dentomaxillofac Radiol* 2008;37:261–7.